

**Received:** 2007.12.11  
**Accepted:** 2008.03.31  
**Published:** 2008.04.XX

# Increased knee cartilage volume in degenerative joint disease using percutaneously implanted, autologous mesenchymal stem cells, platelet lysate and dexamethasone

**Christopher J. Centeno<sup>1</sup>, Dan Busse<sup>2</sup>, John Kisiday<sup>3</sup>, Cristin Keohan<sup>4</sup>, Michael Freeman<sup>5</sup>**

<sup>1</sup> Regenerative Sciences Inc (RSI), Centeno-Schultz Clinic, Westminster, USA

<sup>2</sup> Centeno-Schultz Clinic, Westminster, USA

<sup>3</sup> Colorado State University, USA

<sup>4</sup> Regenerative Sciences Inc (RSI), Westminster, USA

<sup>5</sup> Oregon Health Sciences University and School of Medicine, USA

## Summary

**Background:** The purpose of this study was to see if percutaneously injected autologous mesenchymal stem cells, platelet lysate, and dexamethasone could reduce this patient’s knee cartilage defect size.

**Case Report:** A study patient’s mesenchymal stem cells were obtained from her iliac crest bone marrow, isolated and expanded in culture. They were then injected into her knee along with autologous platelet lysate to enhance growth, and nanogram doses of dexamethasone to promote differentiation to chondrocytes. Pre and post treatment MRI imaging, physical therapy and pain score data were then analyzed.

**Conclusions:** This patient’s MRI data showed a significant decrease in cartilage defect size. Along with this, her measured physical therapy outcomes and subjective pain and functional status all improved. Autologous mesenchymal stem cell injection, in conjunction with platelet lysate and low-dose dexamethasone are a promising minimally invasive therapy for osteoarthritis of the knee.

**Key words:** **Autologous Mesenchymal stem cells • cartilage • osteoarthritis • knee • platelet lysate • Dexamethasone • regeneration**

**Full-text PDF:** <http://www.amjcaserep.com/fulltext.php?ICID=12039>

**Word count:** 3776

**Tables:** 5

**Figures:** 1

**References:** 5

**Author’s address:** Dan Busse, Centeno-Schultz Clinic, 11080 Circle Point Rd Buliding 2, Suite 140. Westminster, CO 80020, USA  
 Phone: (303) 429-6448 PH, e-mail: dan.busse@gmail.com

## BACKGROUND

---

Mesenchymal stem cells are pluripotent cells found in multiple human tissues including bone marrow, synovial tissues, and adipose tissues. They have been shown to differentiate into bone, cartilage, muscle, and adipose tissue and represent a possible promising new therapy in regenerative medicine [1-3]. Because of their multi-potent capabilities, mesenchymal stem cell (MSC) lineages have been used successfully in animal models to regenerate articular cartilage and in human models to regenerate bone [4-8].

The regeneration of articular cartilage via percutaneous introduction of mesenchymal stem cells (MSC's) is a topic of significant scientific and therapeutic interest [9-30]. Stem cells can naturally differentiate to other cell lines such as chondrocytes. However, many practical issues remain before this approach enters mainstream clinical practice. For example, various elements of the local microenvironment can effect MSC differentiation [31-33]. Several authors have shown that dexamethasone acts as a potent differentiating agent for MSC's toward a chondrogenic lineage [34-37]. In addition, it's thought that a scaffolding material might be needed to allow the MSC's to attach and engraft [38-41]. Additionally, isolated bone marrow nucleated cells implanted into degenerated human peripheral joints have shown promise for joint repair [42].

The present case study reports on a successful clinical result using percutaneously implanted, autologous culture expanded MSC's with marrow clot as a scaffold and dexamethasone as a differentiating agent.

## CASE REPORT

---

The research protocol was approved through a non-profit Institutional Review Board (The Spinal Injury Foundation, Westminster CO). Inclusion criteria were as follows:

1. Male or female patients, 18-65 years of age
2. MRI evidence of degenerative knee osteoarthritis
3. Persisting intrusive pain resulting from the condition identified in (2). To ensure that the diagnosis of intrusive osteoarthritis was accurate, diagnostic blocks were used. Confirmation that a joint was a primary cause of the patients' pain was accomplished with a fluoroscopically guided injection of 0.75% Marcaine and 4% Lidocaine into the joint space followed by complete pain relief.
4. The patient had been evaluated by a board certified orthopedic surgeon and informed that they were a knee arthroplasty candidate

## Exclusion criteria:

1. Active inflammatory or connective tissue disease (i.e. lupus, fibromyalgia, RA)
2. Active non-corrected endocrine disorder potentially associated with symptoms (i.e. hypothyroidism, diabetes)
3. Active neurologic disorder potentially associated with symptoms (i.e. peripheral neuropathy, multiple sclerosis)
4. Severe cardiac disease
5. Pulmonary disease requiring medication usage
6. A history of dyspnea or other reactions to transfusion of homologous blood products

## Pre-procedure data collection:

1. CBC and SMAC to rule out unknown medical condition (within 3 months of procedure)
2. The patient was surveyed for activity level

A 46 year-old female was actively recruited by their pain physician from a private interventional pain management practice based on her diagnosis of OA causing significant ongoing pain and disability and their willingness to proceed with the study. This patient was provided with extensive informed consent prior to being enrolled in the study.

## Patient History:

The patient presented with a two year history of right knee pain that began after being kicked in the shin during a martial arts class. She had daily 4-5/10 pain which increased to 7-8/10 with activities such as bending, kneeling, and prolonged walking. Prior treatments included three hyaluronic acid injections and two corticosteroid injections, which resulted in moderate, but short lived symptomatic improvement. Her pain medication regimen included daily glucosamine supplements as well as Ibuprofen and Mobic on an as needed basis.

On initial physical examination there was medial joint line tenderness and a positive patellar grind test. Apley's and McMurray's tests were negative, and there was no ligamentous laxity or joint swelling.

A pre-treatment 3.0 T MRI demonstrated a medial chondral defect on the weight bearing portion of the femur with degenerative thinning of the meniscus.

For one week prior to the marrow harvest procedure the patient was restricted from taking corticosteroids or NSAIDs. Coincident with this harvest procedure, approximately 200cc of heparinized IV venous blood was drawn to be used for platelet lysate (PL). To prepare platelet lysate, platelet rich plasma was prepared

via centrifugation at 200g to separate plasma/platelets from the red blood cells. The supernatant was then drawn off and the platelets pelleted at 1000g centrifugation. The volume of blood serum was reduced so that the platelet concentration was  $1 \times 10^9$  cells/ml. This was considered 100% platelet lysate after a freeze/thaw cycle, which was then diluted to between 10-20% as supplement for serum free cell culture media.

The patient was then placed prone on an OR table and the area to be harvested was numbed with 1% Lidocaine, and a sterile disposable trocar was used to draw 10 cc of marrow blood from the right PSIS area and 10cc from the left PSIS area.

Whole marrow was centrifuged at 100g for 4-6 minutes to separate the plasma from the RBCs. The plasma was removed, placed in a separate tube, and centrifuged at 1000g for 10 minutes to pellet the nucleated cell fraction. The nucleated cells were washed once in PBS, counted, and then re-suspended in DMEM + 10% PL and seeded at  $1 \times 10^6$  cells/cm<sup>2</sup> in monolayer flask culture. Cultures were incubated at 37°C/5% CO<sub>2</sub> in a humidified environment. The culture medium was changed after 3 days, removing the majority of the non-adherent cell population. MSC colonies developed 6-12 days after seeding. After growing to near confluence, the colonies were trypsinized over 30-60 seconds such that only the colony-forming MSCs detached. The MSCs were reseeded at a density of 12,000 cells/cm<sup>2</sup> in  $\alpha$ MEM + 5%, 10%, or 20% PL. Each culture was passaged 1:3 after reaching 40-50% confluence.

After MSC's had been grown to the 5<sup>th</sup> passage, they were suspended in phosphate buffered saline (PBS). The patient returned to the clinic and was consented in writing. The patient was then placed prone on a fluoroscopy table and the bilateral PSIS area was prepped with betadine and sterile drapes. The skin and deeper tissues were then anesthetized with 1% Lidocaine. A sterile trocar was then inserted under fluoroscopy guidance to the superior medial corner of the iliac wing and 10 cc of marrow was drawn. The patient was then quickly turned over and placed supine with the right knee bent at 45 degrees and re-prepped using betadine and sterile gloves. A 25 gauge 2 inch needle was then inserted through a medial inferior approach under c-arm guidance. Once the joint space was attained, 0.25 cc of Isovue contrast

diluted 50% with PBS was injected. Once good medial intra-articular flow was established,  $5.6 \times 10^6$  MSC's suspended in PBS were injected, followed by 10 cc of whole marrow and 1 cc of 10% platelet lysate. The patient was instructed to remain still for one hour to allow for cell attachment and then was instructed to maintain activity as tolerated. The patient returned for two additional 10% intra-articular knee platelet lysate injections (1 cc) at week 1 and week two (post-transplantation). With the two week post transplant platelet lysate supplementation, 1 ml of 10 ng/ml dexamethasone was also injected.

Modified VAS questionnaires and Functional Rating Index [43-44] questionnaires were provided to the patient and administered before the procedure, 1 month after the procedure, and three months after the procedure. The modified VAS is a patient's response to three questions of pain intensity using the standard 1-10 scale, which are then multiplied by a frequency for that complaint. This frequency is determined by the answer to two questions, with numerical increments of 0.25 to 1. A person with significant pain (high VAS) present only with infrequent activity (two frequency multipliers of 0.25) would have a low Modified VAS numerical score. Range of motion measurements of the knee were measured by a physical therapist before the procedure, 1 month post-procedure and 3 months post procedure. In addition, pre-procedure MRI's were obtained on a GE 3.0 T magnet with Proton Density Fast Spin sequences in the sagittal coronal planes. Post procedure images at 1 month and at 3 months were obtained using matching excitation times (NEX), repetition times (TR), and echo times (TE). Quantitative meniscus and articular cartilage volume analysis was carried out using commercially available image processing software (OSIRIS- Digital Imaging Unit, Division of Medical Informatics, University Hospital of Geneva) using three traces by the same independent examiner, of each region of interest (ROI). Standard deviation from the mean was calculated for these three traces. The area of the medial weight bearing femoral defect was also traced and calculated in a similar manner.

## RESULTS

Cell yields upon initial marrow harvest and processing are discussed below in table 1. Note the disparity in the nucleated cell yield from left to right sites. Since

**Table 1.** Cell yields from marrow draw.

Marrow Draw Site	Platelet Count From Whole Marrow million/ml	Nucleated Cell Count millions	RBC Count billions
Left PSIS	780	14	1.64
Right PSIS	992	53	2.16

**Table 2.** MSC Growth in Culture.

Cell Growth Per Day (millions)	
Day 1	0.21
Day 2	
Day 3	0.45
Day 4	
Day 5	0.99
Day 6	
Day 7	2.56
Day 8	
Day 9	3.36
Day 10	
Day 11	5.6
<b>Days in colony = 9</b>	

MSC’s represent approximately 1 in 10,000 nucleated marrow cells, nucleated cell yield is a likely proxy for total MSC’s obtained by the marrow draw.

(caption) Figure 1 shows representative sagittal proton density fast spin MRI images from a GE 3.0T magnet with matching TR and TE from pre-procedure and 2 months post-procedure. Cartilage volume analysis is in Table 4.

(caption) Table 3: The cartilage volume analysis demonstrates a decrease in femoral cartilage defect volume beyond the measured standard deviation of serial measurements.

**Patient Outcomes**

**DISCUSSION**

The pre and post procedure MRI analysis demonstrated a decrease in the volume of the cartilage defect on the medial femoral condyle that was more than the standard deviation of the three ROI measurements.

**Table 3.** Cartilage Volume Analysis in mm<sup>3</sup>.

Image	Area of Measurement	Volume (N=3)	STDEV	SE	% Change from Pre-Injection
Pre-Injection	Cartilage surface	2227	115.82	66.95	
	Meniscus	1533	13	7.51	
	Defect	20.7	1.53	0.88	
6 Months	Cartilage surface	2216	150.7	87.11	<b>-0.49</b>
	Meniscus	1545	35.1	20.29	<b>0.78</b>
	Defect	14.7	1.15	0.67	<b>-28.99</b>

At three month follow-up, modified VAS scores decreased to 0/10. Pain with knee extension decreased from a pre-procedure VAS of 3/10 to 2/10.

**CONCLUSIONS**

This case report shows MRI evidence of femoral chondral healing in this middle aged patient. While there has been evidence from animal models of cartilage regeneration using MSC’s, this is the first case report in a human subject (of which we are aware).

The effects could have been due to the platelet lysate (PL). In our case it was used as a differentiating agent for the mesenchymal stem cells. PL contains multiple growth factors including TGF-beta, IGF, FGF, and PDGF. A literature review of the data on the uses similar substances such as platelet rich plasma shows it has a positive effect on the stimulation of chondrocytes. [45,46]

While the patient reported clinical response could have been due to the Dexamethasone injection provided post transplant procedure, the levels injected (10 ng/ml) were approximately one million times lower than those used clinically (milligram or 1 x 10<sup>-3</sup> vs. nanogram or 1 x 10<sup>-9</sup>). Larger, milligram doses of corticosteroids are commonly used to control inflammation in peripheral joints. This large a dose, however, has been found to cause apoptosis in chondrocytes [47]. However, lower physiologic doses in the nanogram range have been shown to actually increase extracellular matrix production by chondrocytes [48], and are commonly used in-vtro to differentiate MSCs to cartilage [49].

It should be noted that without biopsy, there is no way to determine if the change was fibrocartilage or true hyaline cartilage. Another issue with the clinical result is that the chondral defect was only repaired by approximately 1/3. Thus multiple such treatments may be needed to further heal this type of defect. Of interest, this was a “needle out/needle in” procedure with no activity restriction. Longer term follow-up of this

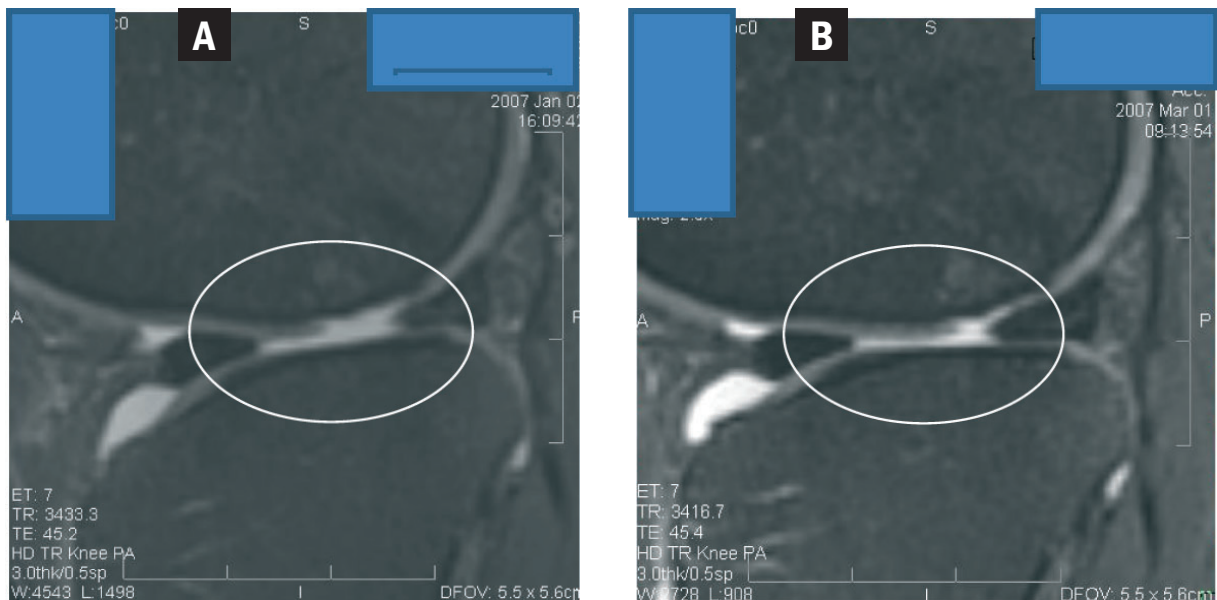


Figure 1. A. Pre Treatment. B. 2 Months Post Treatment.

Table 4. Functional Rating Index and Visual Analog Scores.

Outcome Measures	Pre-Injection	4 Weeks Post	12 weeks Post
Functional Rating Index	17	4	3
Modified VAS	0.67	0.08	0

Table 5. Physical Therapy Outcomes.

Physical Therapy Session	Pre-Session VAS Score	Flexion (deg)	Range of Motion		
			Flexion VAS	Extension (deg)	Extension VAS
Pre Injection Evaluation	2/10	150	2/10	+5	3/10
4 Week post injection	0/10	150	1/10	+5	2/10

patient will continue. Obviously, the generalizability of this technique to the larger population of patients with symptomatic osteoarthritis and traumatic knee injury is unknown. It can be assumed that success rates will vary with age, according to MSC yield, degree of arthritis, and intrinsic regenerative ability.

**ACKNOWLEDGEMENTS**

There were no other contributors to this case report not listed as authors. Financial support came from Regenerative Sciences, INC. and the Centeno-Schultz Clinic

**REFERENCES:**

1. Arnoczky S. P.: Building a meniscus. Biologic considerations. Clin Orthop Relat Res(367 Suppl): S244-53 (1999).
2. Hu X, Wang J, Chen J, Luo R, He A, Xie X, Li J: Optimal temporal delivery of bone marrow mesenchymal stem cells in rats with myocardial infarction. Eur J Cardiothoracic Surg. Mar; 31 (3): 438-43 (2007).
3. Szilvassy S.J.: The biology of hematopoietic stem cells. Arch Med Res, 34(6), 446-60 (2003).
4. Barry F.P.: Mesenchymal stem cell therapy in joint disease. Novartis Found. Symp, 249: p. 86-96; discussion 96-102, 170-4, 239-41 (2003).
5. Buckwalter J.A. and H.J. Mankin: Articular cartilage: degeneration and osteoarthritis, repair, regeneration, and transplantation. Instr Course Lect, 47 487-504 (1998).
6. Caplan A.I.: Mesenchymal stem cell. J Orthop Res, 9(5), 641-50 (1991).
7. Carter D.R., et al: Mechanobiology of skeletal regeneration. Clin Orthop Relat Res. (355 Suppl): p. S41-55 (1998).
8. Johnstone B. and J.U. Yoo: Autologous mesenchymal progenitor cells in articular cartilage repair. Clin Orthop Relat Res, (367 Suppl): S156-62 (1999).
9. Luyten F.P.: Mesenchymal stem cells in osteoarthritis. Curr Opin Rheumatol. 16(5): p. 599-603 (2004).
10. Magne D et al.: Mesenchymal stem cell therapy to rebuild cartilage. Trends Mol Med. 11(11), 519-26. Epub 10/5 2005.
11. Murphy J.M. et al.: Stem cell therapy in a caprine model of osteoarthritis. Arthritis Rheum, 48(12): 3464-74 (2003).
12. Nevo Z., et al.: The manipulated mesenchymal stem cells in regenerated skeletal tissues. Cell Transplant. 7(1), 63-70 (1998).
13. Noel D, F. Djouad, and C. Jorgense: Regenerative medicine through mesenchymal stem cells for bone and cartilage repair. Curr Opin Investig Drugs. 3(7), 1000-4 (2002).



14. Redman S.N., S.F. Oldfield, and C.W. Archer: Current strategies for articular cartilage repair. *Eur Cell Mater*, 9, 23-32; discussion 23-32 (2005).
15. Tallheden T. et al: Phenotypic plasticity of human articular chondrocytes. *J Bone Joint Surg Am*. 85-A Suppl 2, 93-100 (2003).
16. Wakitani S et al. Mesenchymal cell-based repair of large, full-thickness defects of articular cartilage. *J Bone Joint Surg Am* 76(4), 579-92 (1994).
17. Walsh C.J. et al: Meniscus regeneration in a rabbit partial meniscectomy model. *Tissue Eng*, 5(4), 327-37 (1999).
18. Yamasaki T, M Deie et al.: Meniscal regeneration using tissue engineering with a scaffold derived from a rat meniscus and mesenchymal stromal cells derived from rat bone marrow. *J Biomed Mater Res A* 75(1), 23-30 (2005).
19. Gangji V., M Toungouz, et al.: Stem cell therapy for osteonecrosis of the femoral head. *Expert Opin Biol Ther* 5(4), 437-42 (2005).
20. Hernigou P. and F Beaujean: Treatment of osteonecrosis with autologous bone marrow grafting. *Clin Orthop Relat Res* (405): 14-23 (2002).
21. Hernigou P, G Mathieu et al.: Percutaneous autologous bone-marrow grafting for nonunions. surgical technique. *J Bone Joint Surg Am* 88 Suppl 1 Pt 2, 322-7 (2006).
22. Johnstone B. and JU Yoo.: Autologous mesenchymal progenitor cells in articular cartilage repair. *Clin Orthop Relat Res* (367 Suppl): S156-62 (1999).
23. Kanaya A, M Deie, et al.: Intra-articular injection of mesenchymal stromal cells in partially torn anterior cruciate ligaments in a rat model. *Arthroscopy* 23(6), 610-7 (2007).
24. Sakai D, J Mochida et al.: Differentiation of mesenchymal stem cells transplanted to a rabbit degenerative disc model: potential and limitations for stem cell therapy in disc regeneration. *Spine* 30(21), 2379-87 (2005).
25. Sakai D, J Mochida et al.: Transplantation of mesenchymal stem cells embedded in Atelocollagen gel to the intervertebral disc: a potential therapeutic model for disc degeneration. *Biomaterials* 24(20), 3531-41 (2003).
26. Wakitani S, T Goto et al.: Mesenchymal cell-based repair of large, full-thickness defects of articular cartilage. *J Bone Joint Surg Am* 76(4), 579-92 (1994).
27. Walsh CJ, D Goodman et al.: Meniscus regeneration in a rabbit partial meniscectomy model. *Tissue Eng* 5(4), 327-37 (1999).
28. Yamasaki T, M Deie et al.: Meniscal regeneration using tissue engineering with a scaffold derived from a rat meniscus and mesenchymal stromal cells derived from rat bone marrow. *J Biomed Mater Res A* 75(1), 23-30 (2005).
29. Agung M, Ochi M, Yanada S, Adachi N, Izuta Y, Yamasaki T, Toda K.: Mobilization of bone marrow derived mesenchymal stem cells into the injured tissues after intraarticular injection and their contribution to tissue regeneration. *Knee Surg Sports Traumatol Arthrosc*. Dec 14(12): 1307-14 (2006).
30. Nishimori M, Deie M, Kanaya A, Exham H, Adachi N, Ochi M Repair of chronic osteochondral defects in the rat. A bone marrow-stimulating procedure enhanced by cultured allogenic bone marrow mesenchymal stromal cells. *J Bone Joint Surg Br*. Sept: 88(9), 1236-44 (2006).
31. Kellinsalmi M, Parikka V, Risteli J, Hentunen T, Leskela HV, Lehtonen S, Selander K, Vaananen K, Lehenkali P: Inhibition of cyclooxygenase-2 down-regulates osteoclast and osteoblast differentiation and favours adipocyte formation in vitro. *Eur J Pharmacol*. Jun 29; [Epub ahead of print] (2007).
32. Lee JS, Lee JS, Roh HL, Kim CH, Jung JS, Suh KT: Alterations in the differentiation ability of mesenchymal stem cells in patients with nontraumatic osteonecrosis of the femoral head: comparative analysis according to the risk factor. *J Orthor Res*. Apr; 24(4), 604-9 (2006).
33. Ward DF, Salasznyk RM, Klees RF, Backiel I, Agius P, Bennett K, Boskey A, Plopper GE: Mechanical strain enhances extracellular matrix-induced gene focusing and promotes osteogenic differentiation of human mesenchymal stem cells through an extracellular-related kinase-dependent pathway. *Stem Cells Dev*. Jun; 16(3), 467-80 (2007).
34. Yokoyama A, Muneta T, Nimura A, Koga H, Mochizuki T, Hata Y, Sekiya I FGF2 and dexamethasone increase the production of hyaluronan in two-dimensional culture of elastic cartilage-derived cells: in vitro analyses and in vivo cartilage formation. *Cell Tissue Res*. Jun 22; [Epub ahead of print] (2007).
35. Scutt, A. and P. Bertram: Basic fibroblast growth factor in the presence of dexamethasone stimulates colony formation, expansion, and osteoblastic differentiation by rat bone marrow stromal cells. *Calcif Tissue Int* 64(1), 69-77 (1999).
36. Both SK, van del' Muijsenberg AJ, van Blitterswijk CA, de Boer J, de Bruijn JD: A rapid and efficient method for expansion of human mesenchymal stem cells. *Tissue Eng*. Jan; 13(1): 3-9 (2007).
37. Takagi M, Umetsu Y, Fujiwara M, Wakitani S: High inoculation cell density could accelerate the differentiation of human bone marrow mesenchymal stem cells to chondrocyte cells. *J Biosci Bioeng*. Jan; 103(1), 98-100 (2007).
38. Fan H, Hu Y, Zhang C, Li X, Lv R, Qin L, Zhu R: Cartilage regeneration using mesenchymal stem cells and a PLGA-gelatin/chondroitin/hyaluronate hybrid scaffold. *Biomaterials*. Sep; 27(26), 4573-80. Epub 2006 May 23 (2006).
39. Nuttelman CR, Tripodi MC, Anseth KS: In vitro osteogenic differentiation of human mesenchymal stem cells photoencapsulated in PEG hydrogels. *J Biomed Mater Res A*. Mar 15; 68(4), 773-82 (2004).
40. B Malafaya PP, Pedro AJ, Peterbauer A, Gabriel C, Redl H, Reis RL (2005). Chitosan particles agglomerated scaffolds for cartilage and osteochondral tissue engineering approaches with adipose tissue derived stem cells. *J Mater Sci Mater Med*. Dec; 16(12): 1077-85 (2005).
41. Guo X, Wang C, Zhang Y, Xia R, Hu M, Duan C, Zhao Q, Dong L, Lu J, Qing Song Y: Repair of large articular cartilage defects with implants of autologous mesenchymal stem cells seeded into beta-tricalcium phosphate in a sheep model. *Tissue Eng*. Nov-Dec 10 (11-12): 1818-29 (2004).
42. Centeno CJ et al.: Partial regeneration of the human hip via autologous bone marrow nucleated cell transfer: A case study. *Pain Physician* 9(3), 253-6 (2006).
43. Childs JD, Piva SR: Psychometric properties of the functional rating index in patients with low back pain. *Eur Spine J*. Dec;14(10), 1008-12. Epub 2005 Apr 15.
44. Bayar B, Bayar K, Yakut E, Yakut Y. Reliability and validity of the Functional Rating Index in older people with low back pain: preliminary report. *Aging Clin Exp Res*. Feb; 16(1), 49-52 (2004).
45. Akeida K, An HS, Okuma M, Attawia M, Miyamoto K, Thonar EJ, Lenz ME, Sah RL, Masuda K. Platelet-rich plasma stimulates porcine articular chondrocyte proliferation and matrix biosynthesis. *Osteoarthritis Cartilage*. Dec; 14(12): 1272-80. Epub 2006 Jul 3.
46. Wu W, Chen F, Liu Y, Ma Q, Mao T. Autologous injectable tissue-engineered cartilage by using platelet-rich plasma: experimental study in a rabbit model. *J Oral Maxillofac Surg*. Oct;65(10): 1951-7 (2007).
47. Chrysis D, Ritzen EM, Savendahl L. Growth retardation induced by dexamethasone is associated with increased apoptosis of the growth plate chondrocytes. *J Endocrinol*. Mar; 176(3): 331-7 (2003).
48. Richardson DW, Dodge GR. Dose dependant effects of corticosteroids on the expression of matrix-related genes in normal and cytokine-treated articular chondrocytes. *Inflamm Res*. Ja; 52(1): 39-49 (2003).
49. Grigoriadis AE, Heersche JN, Aubin E. Differentiation of muscle, fat, cartilage, and bone from progenitor cells present in a bone-derived clonal cell population: effect of dexamethasone. *J Cell Biol*. Jun, 106(6): 2139-51 (1988).