


Available online at www.sciencedirect.com

ScienceDirect

www.elsevier.com/locate/trap

Interventional orthopedics in pain medicine practice

Christopher J. Centeno, MD*, Christopher J. Williams, MD,
Matthew Hyzy, DO

Centeno-Schultz Clinic, 403 Summit Blvd, Broomfield, Colorado 80021

ARTICLE INFO

Keywords:

Mesenchymal stem cells
MSCs
Interventional orthopedics
Musculoskeletal
Interventional pain management
Stem cells
Regenerative medicine
Regenerative orthopedics

ABSTRACT

Interventional pain physicians are in a unique place to take advantage of regenerative medicine technology to improve patient outcomes and decrease the invasiveness of orthopedic procedural care. However, that sea of change would take significant changes to the educational system similar to those established when interventional spine was first introduced as a subspecialty. The tenets of interventional orthopedics are as follows: injectates that can facilitate healing of musculoskeletal tissues, precise placement of those injectates into damaged structures using imaging guidance, and the eventual development of new tools to facilitate percutaneous tissue manipulation. Stem cells are an early injectate being used in this developing field. The research supporting the use of stem cells to treat orthopedic conditions is more robust than many realize. Early clinical work to treat osteonecrosis and fracture nonunion began in the 1990s. Today, early clinical evidence to support the use of bone marrow concentrate to treat knee osteoarthritis and other orthopedic conditions exists and continues to develop. Although more research needs to be completed, the increased availability of biologic agents that can prompt healing in musculoskeletal tissues would usher in a new field of medicine—interventional orthopedics.

© 2016 Elsevier Inc. All rights reserved.

Background

It has been observed that the use of platelet-rich plasma (PRP) and stem cells is rapidly expanding.^{1–6} This use is likely altering the orthopedic care landscape in disruptive ways. In addition, interventional pain physicians have unique skills that would allow them to take advantage of this technology to decrease the invasiveness of orthopedic procedural care. However, that shift away from surgical orthopedics to interventional care would take significant changes to the educational system similar to those established for interventional spine. Finally, new technologies that improve the tissue healing ability of injectates and allow percutaneous manipulation of tissue would broaden nonsurgical care options.

In 1989, the coronary artery bypass graft rate for coronary artery disease was 141/100,000. By 2015, it was 60/100,000, a 59% drop.⁷ The likely reason for the dramatic reduction in cardiothoracic surgery rates is the adoption of interventional cardiology, allowing less invasive ways to restore normal coronary circulation. We are poised on the brink of the same change in orthopedic care.

Autologous biologics include PRP and stem cell therapies. PRP contains numerous cytokines that degranulate from whole platelets to enhance tissue repair.^{8,9} Early clinical studies in the use of PRP for orthopedic conditions have shown promise in treating epicondylitis, achilles tendinitis, and knee osteoarthritis (OA).^{9–12} Another category within autologous biologics includes stem cell therapies. The most

*Corresponding author.

E-mail address: centenoffice@centenoschultz.com (C.J. Centeno).

Table 1 – Summary of research articles on the use of bone marrow MSCs for the treatment of knee osteoarthritis. (Reproduced with permission from The Centeno-Schultz clinic.)

Author	Study type	Intervention	Patient no	Stem cell origin	Functional improvement	Notes
Vagsness	DB RCT	Partial meniscectomy with MSC vs Placebo	55	Allogenic cultured BMA MSC	Yes	1/4 Patients with increased meniscus volume
Centeno	Prospective case series	Precise image-guided injection	840	Bone marrow concentrate	Yes	2/3 of patients were TKA candidates
Kim	Prospective case series	Injection	49	Auto cultured BMA MSC	Yes	Full-thickness chondral lesions < 6 cm ²
Vega	RCT	Injection of MSC vs HA	30	Allogenic cultured BMA MSC	Yes	Improved cartilage signal on MRI T2 mapping
Koh	RCT	Knee MFX or stem cells vs MFX	44	Auto cultured adipose MSC	Yes	Better lesion coverage or MRI signal. No change on second-look arthroscopy

BMA, bone marrow aspirate; DB, double-blind; MRI, magnetic resonance imaging; MFX, microfracture; MSC, mesenchymal stem cell; RCT, randomized controlled trial; TKA, total knee arthroplasty.

common type deployed in orthopedics is the isolation of the centrifuged bone marrow fraction that contains mesenchymal and hematopoietic stem cells, otherwise known as bone marrow concentrate (BMC) or bone marrow aspirate concentrate.⁸

The status of BMC research

The field of autologous biologics has the potential to alter the playing field of orthopedic care by allowing percutaneous injections to replace the need for more invasive orthopedic surgeries. Take, for example, the use of BMC. As of 4/3/16, the total number of all patients who have been treated for orthopedic conditions for any type of bone marrow stem cell therapy and had their results (outcomes or adverse events) published and listed in the US Library of Medicine is 8428.¹³ The disease areas with most outcome and complications information published are hip osteonecrosis and knee OA (Tables 1 and 2).

Other studies have been published for hip OA, shoulder rotator cuff, lumbar degenerative disk disease, and ankle OA.¹⁴⁻¹⁷

The commonality among many of the studies being published in this area of autologous biologics is that many involve peripheral joint injection with or without surgery. For example, in the review of bone marrow stem cell

therapy cited earlier, more than a third of the studies were injection alone (28/77) and more than half were surgery and injection (39/77). This is likely owing to just injecting and infiltrating the damaged orthopedic tissue such as tendon, ligament, cartilage, or bone may help enhance healing, leaving many types of orthopedic conditions treatable without surgery.

The first studies of the clinical effects of BMC on hip osteonecrosis and fracture nonunion were published in the 1990s. The largest study ($n = 342$) demonstrated that osteonecrotic ARCO grade 1-2 hips demonstrated approximately an 80% likelihood of not requiring arthroplasty at 10-year follow-up when treated with a percutaneous injection of BMC.¹⁸ In the largest case series of fracture nonunion, 53/60 patients treated with surgical grafts containing BMC had healed at 4 months. The 7 patients who did not heal, had the lowest concentration of stem cells.¹⁹

For knee OA, several small randomized controlled trials using autologous and allogenic culture expanded mesenchymal stem cells have been published²⁰⁻²⁴ (Table 1). These studies all demonstrated satisfactory clinical results with the Vagsness study demonstrating that 1 in 4 patients with an increase in meniscus volume and the Vega study showing improvement in magnetic resonance imaging measured cartilage signal.^{20,23} The authors large case series using BMC also reported promising outcomes with the additional finding that

Table 2 – Summary of research articles on the use of bone marrow MSCs for the treatment of hip osteoarthritis. (Reproduced with permission from The Centeno-Schultz clinic.)

Author	Study type	Intervention	Patient no	Stem cell origin	Functional improvement	Notes
Centeno	Prospective case series	Precise image-guided injection	196	Bone marrow concentrate	Yes	Most patients were THA candidates
Emadedin	Prospective case series	Image guided injection	5	Culture expanded BM MSC	Yes	Severity unknown

BM, bone marrow; MSC, mesenchymal stem cell; THA, total hip arthroplasty.

Table 3 – Summary of research articles on the use of bone marrow MSCs for the treatment of degenerative disk disease. (Reproduced with permission from The Centeno-Schultz clinic.)

Author	Study type	Intervention	Patient no	Stem cell origin	Functional improvement	Notes
Mochida	Prospective case series	Surgical implant	9	Auto nucleus pulposus cells	No. Minimal MRI improvement.	Safety study
Pettine	Prospective case series	Injection into IVD	26	Bone marrow concentrate	Yes	Possible changes in MRI
Pang	Prospective case series	Surgical implantation	2	Allogenic cord blood MSC's	Yes	No imaging
Orozco	Prospective case series	Injection into IVD	10	Auto culture expanded BM MSC	Yes	No improvement in disk height, some change in T2 signal

BM, bone marrow; IVD, intervertebral disk; MRI, magnetic resonance imaging; MSC, mesenchymal stem cell.

adding an adipose graft to BMC did not improve patient reported outcome over just injecting BMC alone.²²

The efficacy regarding the use of BMC in other peripheral joints has also been published. For example, 2 articles exist in the literature on hip OA^{22,25} (Table 2), both showing reasonable efficacy. Similarly, multiple articles exist suggesting that BMC or culture expanded mesenchymal stem cells may reduce symptoms and improve the appearance of the intervertebral disk in degenerative disk disease^{14,26-28} (Table 3).

What is interventional orthopedics?

Recently, one of the authors (C.C.) coined a term that borrowed from our colleagues in cardiology that is based on the idea that when new technology is introduced, surgical disciplines get morphed into percutaneous interventional specialties. That term is “interventional orthopedics” (IO). At its core, IO is the use of ever more sophisticated injectates and tools to allow orthopedic conditions once treated through surgical means to be treated less invasively using percutaneous injections. The core tenets of this new medical specialty are

- (1) injectates that can facilitate healing of bone, tendon, ligament, muscle, or cartilage;
- (2) precise placement of those injectates into damaged structures using imaging guidance; and
- (3) the eventual development of new tools to facilitate percutaneous tissue manipulation.

Although physicians who are trained in interventional spine care understand how to inject many of the component parts of the spine with fluoroscopic guidance, much of orthopedic care includes peripheral joint injuries.^{29,30} However, we have observed that scarce attention is paid in the curriculum of interventional spine fellowships to education on peripheral joint injection. Hence, educational changes are likely needed for IO to realize its full potential.

IO requires the ability to accurately place injectates into parts of the peripheral joints that are not readily visible under fluoroscopy. For example, ultrasound is superior for imaging of the soft tissues such as tendons, ligaments, and muscles.^{31,32}

However, in our experience, very few interventional spine fellowships provide extensive training in peripheral joint ultrasound.

Yet another aspect of treating peripheral joints is a solid understanding of their biomechanics, injury mechanisms, and evidence-based treatments available. Although interventional spine fellowships may focus on these issues for the spine, they do not generally cover these areas of study for peripheral joints. These topics are more commonly taught in a sports medicine fellowship.³³ In addition, although an interventional spine fellowship is fluoroscopically centric, a sports medicine fellowship is commonly ultrasound centric.^{33,34}

Pain management skills are critical for IO

Our team has been working on the treatment of knee anterior cruciate ligament (ACL) tears with BMC for many years. We have published an early case series using computerized magnetic resonance imaging analysis of the ligament that showed promising objective evidence of changes in imaging consistent with healing.³⁵ The technique for cell placement has evolved through our many years of study on this topic (Figure 1).

First, although ACL reconstruction has been the gold standard for the treatment of symptomatic, high-grade ACL tear, it is a procedure with many issues. Because of the reconstruction, the original ACL is detached and the tendon graft is placed at a more vertical angle. This does not prevent the anterior motion of the tibia on the femur with the same efficiency as the original ACL. This extra movement can increase the likelihood of OA.³⁶ For example, a recent research investigation found that 67% of teens (age 10-16 years) who underwent ACL reconstruction surgery had imaging signs of OA by 30 years of age.³⁷ In addition, in procedures where an autograft is used, the muscle from which the tendon graft is harvested usually does not regain normal strength. For example, a recent study of hamstring allograft ACL procedures demonstrated that 25% of patients had shortening of the hamstring, whereas more than 30% had weakness in the muscle, and 10%-40% reported atrophy.³⁸ These strength deficits may lead to increased tibial rotation with reduced neuromuscular control during pivoting sports or landing, increasing load on hyaline cartilage, and thus increasing the risk of reinjury. Hence, if it were possible to retain the original ACL by healing the tear in situ, many of these issues may be avoided.

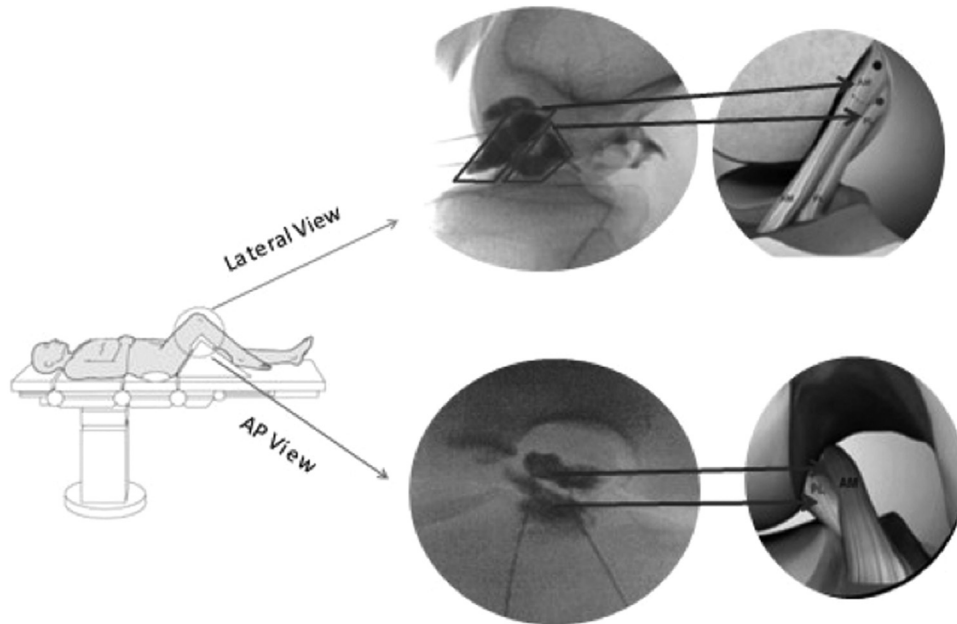


Fig. 1 – ACL double bundle injection: patient is placed in supine position on examination table with target knee bent (as shown) to obtain AP and lateral views of the ACL. Using fluoroscopy, 2 separate 25 gauge 3.5 in. needles are inserted toward the origin and insertion of ACL. Once needles are in correct location, specific bundles are targeted with contrast dye outlining each bundle and placing bone marrow concentrate into each location. AP, anteroposterior. (Reproduced with permission from The Centeno-Schultz clinic.)

We initially attempted the use of ultrasound and fluoroscopy, trying to find the best technology to accurately place the injectate into as much of the torn ligament as feasible. The limitation of ultrasound is that it only demonstrates the distal insertion of the ACL (Figure 2). The origin of the ligament in the lateral trochlear groove is not visualized. In addition, using fluoroscopic injection techniques with contrast, we have demonstrated that the posterior aspect of the synovial sheath

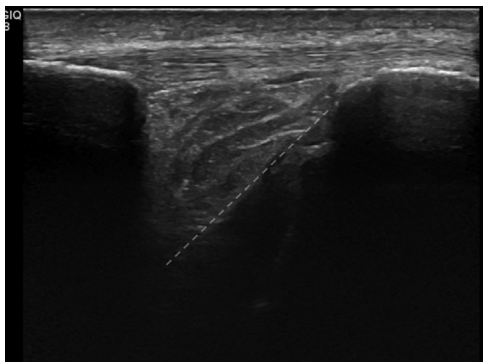


Fig. 2 – The knee ACL as seen on long-axis ultrasound (probe canted in the same plane as the ligament and imaging with the patient's knee in hyperflexion through the patellar ligament). The femur is to the left and the tibia to the right of the image. Note that the gray dashed line shows the course of the ligament, which is hyperechoic at its distal anterior insertion and hypoechoic at its mid-portion. The proximal origin in the lateral trochlear groove is not visualized. (Color version of figure is available online.) (Reproduced with permission from The Centeno-Schultz clinic.)

of many injured ligaments is not intact, leading to extravasation of injectate through a posterior tear that seems common in these injuries (Figure 3). It would then reason that this reduces the likelihood of the autologous biologic being able to traverse this area and infiltrate into the proximal fibers at the lateral trochlear groove to the point of the bony origin. Hence, we have developed an injection technique that also catches the ligament superiorly at its origin. As discussed, ultrasound is unable to adequately image this area. In addition, in this ligament, ultrasound provides scarce data on how much of the ACL ligament has been covered with injectate, although fluoroscopy can easily document this through contrast spread.

Another complicating factor in injecting ACLs is that there are 2 bundles of the ligament—the anterior-medial and

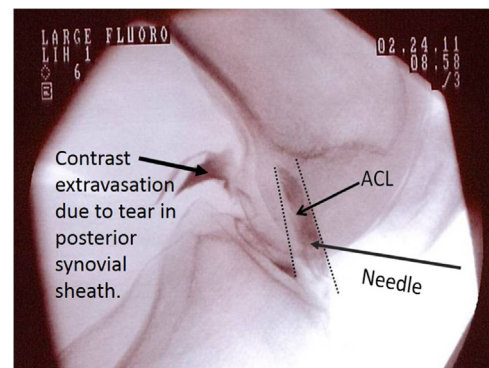


Fig. 3 – Immediate contrast extravasation on a lateral knee fluoroscopy image from a tear in the posterior synovial sheath of the ACL. (Reproduced with permission from The Centeno-Schultz clinic.)

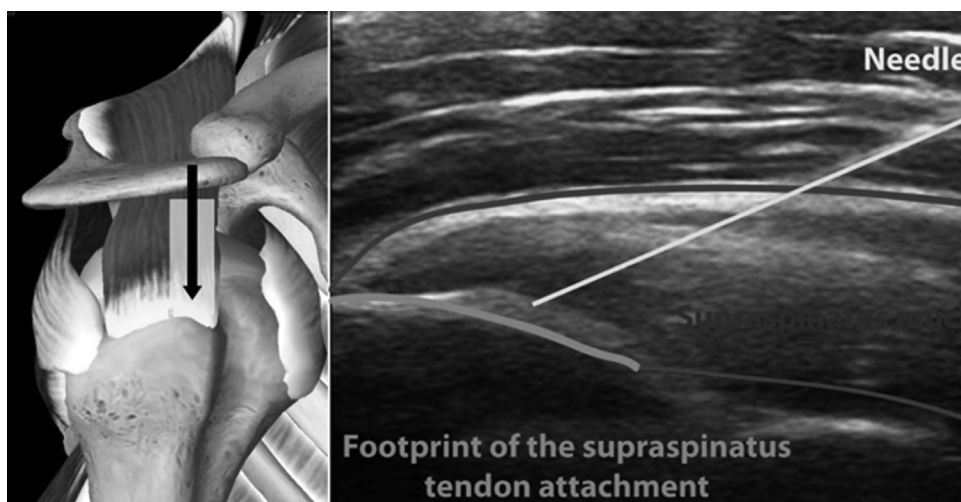

Fig. 4 – An injection under ultrasound of the supraspinatus tendon at its footprint, demonstrating the ability of the technology to demonstrate the high-quality visualization of the tendon. (Reproduced with permission from The Centeno-Schultz clinic.)

posterior-lateral.³⁹ This 2-bundle system adds rotational stability in addition to anterior-posterior stability.⁴⁰ This complexity of the anatomy also adds to the complexity of the injection technique in that both bundles need to be injected with adequate documentation of that coverage.

In summary, the knee ACL is an example of how the fluoroscopy guidance skills acquired in a traditional sports medicine or pain management training programs can be applied in IO. Conversely, this thought exercise also flows in the opposite direction. For example, although ultrasound can be used to perform simple epidural injections in the spine, it is incapable of following the injectate behind bony structures such as the lamina or pedicle, which may result in suboptimal injectate placement.^{41,42} Hence, for IO to achieve its lofty goal of becoming a new medical specialty, both technologies need to be combined or each used for its strengths.

Can we enhance pain management practice with IO?

As discussed, ultrasound skills for peripheral joint injections allow much more accurate placement of injectate into areas such as tendon, where the structure can be directly observed (Figure 4). Hence, it would seem that ultrasound training is a key component of IO and that adding this component to existing pain management and sport medicine fellowships would, therefore, be helpful. In addition, IO fellows would need exposure and training to peripheral joint physical examination and the knowledge of the evidence base for orthopedic medicine and surgery.

IO: future directions

If the past is prologue, less invasive percutaneous procedures that are capable of delivering biologics capable of healing to specific areas of injury in the musculoskeletal system that offer equal or better outcomes as traditional surgical procedures with less complications should gradually replace many

elective orthopedic procedures. Already, the evidence base for orthopedic surgery is, as an author puts it as “scandalously poor.”⁴³ Hence, IO can find its place through continued publication of high-level research that shows superior outcomes when surgery is avoided.

In addition, although the early efforts of the rapidly growing specialty include the precise placement of autologous biologics, the future is likely to see many more types of injectates as well as new tools to manipulate tissue. For example, recombinant growth factors may help to speed the work of autologous biologics or act on their own to facilitate tissue healing. Genetically engineered, mass-produced cells with superior healing properties may well one day replace autologous tissues. In addition, the ability to bring tissue together through a percutaneous procedure and adhere it, would revolutionize the field. One could also easily imagine the percutaneous placement of anchors and other implantable devices that would allow IO to compete directly with surgical orthopedics for many applications.

In summary, the field of IO is being spontaneously created owing to changes in technology and the need for nonsurgical alternatives. Although organization of the physicians trained to provide this care is needed as well as retraining and educational standards, the landscape of orthopedic care is being dramatically altered in the process. As Heraclitus once said, “There is nothing permanent except change.”⁴⁴

REFERENCES

1. Centeno CJ, Bashir J. Safety and regulatory issues regarding stem cell therapies: one clinic's perspective. *PM R*. 2015;7(4 suppl):S4–S7.
2. Chen FM, Liu X. Advancing biomaterials of human origin for tissue engineering. *Prog Polym Sci*. 2016;53:86–168.
3. Dhillon MS, et al. Orthobiologics and platelet rich plasma. *Indian J Orthop*. 2014;48(1):1–9.
4. Gobbi A, Whyte GP. One-stage cartilage repair using a hyaluronic acid-based scaffold with activated bone marrow-derived mesenchymal stem cells compared with microfracture: five-year follow-up. *Am J Sports Med*. 2016;44(11):2846–2854.

5. Ohishi M, Schipani E. Bone marrow mesenchymal stem cells. *J Cell Biochem*. 2010;109(2):277–282.
6. Sampson S, Botto-van Bemden A, Aufiero D. Autologous bone marrow concentrate: review and application of a novel intra-articular orthobiologic for cartilage disease. *Phys Sportsmed*. 2013;41(3):7–18.
7. Diodato M, Chedrawy EG. Coronary artery bypass graft surgery: the past, present, and future of myocardial revascularisation. *Surg Res Pract*. 2014;2014:726158.
8. Boswell SG, et al. Platelet-rich plasma: a milieu of bioactive factors. *Arthroscopy*. 2012;28(3):429–439.
9. Karaduman M, et al. Platelet-rich plasma versus open surgical release in chronic tennis elbow: a retrospective comparative study. *J Orthop*. 2016;13(1):10–14.
10. Meheux CJ, et al. Efficacy of intra-articular platelet-rich plasma injections in knee osteoarthritis: a systematic review. *Arthroscopy*. 2016;32(3):495–505.
11. Guelfi M, et al. Long-term beneficial effects of platelet-rich plasma for non-insertional Achilles tendinopathy. *Foot Ankle Surg*. 2015;21(3):178–181.
12. Gaweda K, Tarczynska M, Krzyzanowski W. Treatment of Achilles tendinopathy with platelet-rich plasma. *Int J Sports Med*. 2010;31(8):577–583.
13. Centeno CJ. *Orthopedic Stem Cell Research Summary*. Centeno-Schultz Clinic; Online; 2016.
14. Orozco I, et al. Intervertebral disc repair by autologous mesenchymal bone marrow cells: a pilot study. *Transplantation*. 2011;92(7):822–828.
15. Hernigou P, et al. Biologic augmentation of rotator cuff repair with mesenchymal stem cells during arthroscopy improves healing and prevents further tears: a case-controlled study. *Int Orthop*. 2014;38(9):1811–1818.
16. Giannini S, et al. One-step bone marrow-derived cell transplantation in talar osteochondral lesions. *Clin Orthop Relat Res*. 2009;467(12):3307–3320.
17. Daltro GC, et al. Efficacy of autologous stem cell-based therapy for osteonecrosis of the femoral head in sickle cell disease: a five-year follow-up study. *Stem Cell Res Ther*. 2015; 6:110.
18. Hernigou P, et al. Stem cell therapy for the treatment of hip osteonecrosis: a 30-year review of progress. *Clin Orthop Surg*. 2016;8(1):1–8.
19. Hernigou P, et al. Percutaneous autologous bone-marrow grafting for nonunions. Surgical technique. *J Bone Joint Surg Am*. 2006;88(suppl 1 Pt 2):322–327.
20. Vangsness CT Jr, et al. Adult human mesenchymal stem cells delivered via intra-articular injection to the knee following partial medial meniscectomy: a randomized, double-blind, controlled study. *J Bone Joint Surg Am*. 2014;96(2): 90–98.
21. Kim YS, Choi YJ, Koh YG. Mesenchymal stem cell implantation in knee osteoarthritis: an assessment of the factors influencing clinical outcomes. *Am J Sports Med*. 2015;43(9):2293–2301.
22. Centeno C, et al. Efficacy of autologous bone marrow concentrate for knee osteoarthritis with and without adipose graft. *Biomed Res Int*. 2014;2014:370621.
23. Vega A, et al. Treatment of knee osteoarthritis with allogeneic bone marrow mesenchymal stem cells: a randomized controlled trial. *Transplantation*. 2015;99(8):1681–1690.
24. Koh YG, et al. Adipose-derived mesenchymal stem cells with microfracture versus microfracture alone: 2-year follow-up of a prospective randomized trial. *Arthroscopy*. 2016;32(1):97–109.
25. Emadedin M, et al. Long-term follow-up of intra-articular injection of autologous mesenchymal stem cells in patients with knee, ankle, or hip osteoarthritis. *Arch Iran Med*. 2015;18(6):336–344.
26. Pettine KA, et al. Percutaneous injection of autologous bone marrow concentrate cells significantly reduces lumbar discogenic pain through 12 months. *Stem Cells*. 2015;33(1):146–156.
27. Mochida J, et al. Intervertebral disc repair with activated nucleus pulposus cell transplantation: a three-year, prospective clinical study of its safety. *Eur Cell Mater*. 2015;29:202–212 [discussion 212].
28. Pang X, Yang H, Peng B. Human umbilical cord mesenchymal stem cell transplantation for the treatment of chronic discogenic low back pain. *Pain Physician*. 2014;17(4):E525–E530.
29. Conway JA, et al. A survey of ultrasound training in U.S. and Canadian chronic pain fellowship programs. *Pain Med*. 2015; 16(10):1923–1929.
30. Asaad BO, et al. A survey on teaching ultrasound-guided chronic pain procedures in pain medicine fellowship programs. *Pain Physician*. 2014;17(6):E681–E689.
31. Henderson RE, Walker BF, Young KJ. The accuracy of diagnostic ultrasound imaging for musculoskeletal soft tissue pathology of the extremities: a comprehensive review of the literature. *Chiropr Man Therap*. 2015;23:31.
32. Jacobson JA. Musculoskeletal ultrasound: focused impact on MRI. *AJR Am J Roentgenol*. 2009;193(3):619–627.
33. Henehan M, Shiple B, Coppola G. Nonsurgical sports medicine training in the United States: a survey of sports medicine fellowship graduates. *Clin J Sport Med*. 2003;13(5):285–291.
34. Finnoff JT, et al. American Medical Society for Sports Medicine recommended sports ultrasound curriculum for sports medicine fellowships. *Br J Sports Med*. 2015;49(3):145–150.
35. Centeno CJ, et al. Anterior cruciate ligament tears treated with percutaneous injection of autologous bone marrow nucleated cells: a case series. *J Pain Res*. 2015;8:437–447.
36. Simon D, et al. The relationship between anterior cruciate ligament injury and osteoarthritis of the knee. *Adv Orthop*. 2015;2015:928301.
37. Li RT, et al. Predictors of radiographic knee osteoarthritis after anterior cruciate ligament reconstruction. *Am J Sports Med*. 2011; 39(12):2595–2603.
38. Nomura Y, Kuramochi R, Fukubayashi T. Evaluation of hamstring muscle strength and morphology after anterior cruciate ligament reconstruction. *Scand J Med Sci Sports*. 2015;25(3):301–307.
39. Petersen W, Zantop T. Anatomy of the anterior cruciate ligament with regard to its two bundles. *Clin Orthop Relat Res*. 2007;454:35–47.
40. Amis AA. The functions of the fibre bundles of the anterior cruciate ligament in anterior drawer, rotational laxity and the pivot shift. *Knee Surg Sports Traumatol Arthrosc*. 2012;20(4):613–620.
41. Evans I, et al. Ultrasound versus fluoroscopic-guided epidural steroid injections in patients with degenerative spinal diseases: a randomised study. *Eur J Anaesthesiol*. 2015;32(4):262–268.
42. Provenzano DA, Narouze S. Sonographically guided lumbar spine procedures. *J Ultrasound Med*. 2013;32(7):1109–1116.
43. Lohmander LS, Roos EM. The evidence base for orthopaedics and sports medicine. *Br Med J*. 2015;350:g7835.
44. Heraclitus. In: *Brainy Quote*. Unknown; Online. p. Historical Quote.